

An Unusual Case of Myelitis with Myositis

NEERA CHOUDHARY¹, PRASHANT MAKHIJA², VINOD PURI³, GEETA ANJUM KHWAJA⁴, ASHISH DUGGAL⁵

ABSTRACT

The Chikungunya virus belonging to genus alphavirus and family togaviridae causes an arthropod-borne self-limiting febrile illness in humans. Neurological complications are rare with myelitis being even a rarer presentation. We report here a patient with Chikungunya fever who developed acute transverse myelitis with myositis during the convalescent period.

Keywords: Chikungunya, Myopathy, Spinal cord

CASE REPORT

An 18-year-old man, waiter in a city restaurant, presented to neurology department of a tertiary care hospital with acute onset weakness and sensory loss of all four limbs along with painful urinary retention of 3 days duration. He had recently recovered from a bout of febrile illness which he contacted while working in his village farms. Though the fever had subsided but the bodyache which accompanied it, still persisted. After about two weeks of the subsidence of his fever, patient developed acute onset weakness and sensory loss of all four limbs along with painful urinary retention. The weakness was asymmetrical, he could not move his right half of body at all though he could lift his left upper and lower limb just above the plane but was unable to bear weight on his left lower limb and needed to be supported by two persons to walk. Though he had the urge to pass urine but was unable to do so and had pain in his lower abdomen. Patient was shifted in a vehicle to the hospital and while on way he developed respiratory distress. By the time he reached hospital the respiratory distress had increased to the extent that he had to be intubated and he was relieved of his urinary retention by catheterization.

On clinical evaluation patient was conscious responding by gestures as he was intubated, limited cranial nerve examination possible including fundus was normal. There was hypotonia in all 4 limbs and there was tenderness on muscle palpation. Power was 0/5 in right upper & lower limbs and 3/5 in left upper and lower limbs. Deep tendon reflexes (DTRs) were all absent, plantars mute, he had reduced sensory perception to pinprick below clavicle on the right side and below the nipple on the left side.

A clinical possibility of acute partial transverse myelitis with myositis was kept and patient was investigated accordingly [Table/Fig-1].

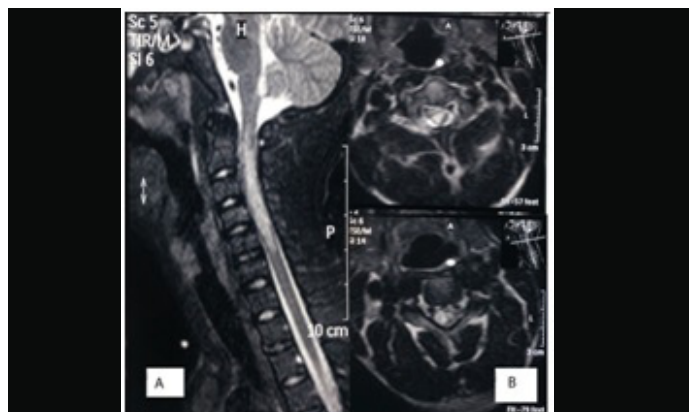
MRI of the spine showed a T2/FLAIR hyperintense signal extending from cervicomedullary junction to C6 level [Table/Fig-2], a

Investigation	Result
ESR	80mm/1 st hour
SGOT	72 IU/L
SGPT	94 IU/L
CPK	1633 IU/L
CSF	
Cells	2 cells all lymphocytes
Protein	79mg/dl
Sugar	94.5 mg/dl

[Table/Fig-1]: Routine Investigations of the patient.

corresponding imaging study of the brain was normal. Serological studies were positive for Chikungunya IgM ELISA while connective tissue and vasculitic profile screening (ANA, dsDNA, cANCA, pANCA), Dengue NS1 antigen and IgM ELISA, leptospirosis IgM ELISA, ELISA for HIV I & II, HBsAg and anti-HCV were all negative.

He was started on injectable methylprednisolone followed by oral steroids with which he showed minimal improvement in his weakness with a significant drop in his Creatine Phosphokinase (CPK) level (from 1633 to 92 IU/L in two weeks) and he was gradually weaned off the ventilator after 3 weeks. Subsequently there was a gradual recovery in his motor power and he was able to ambulate with support.



[Table/Fig-2]: (a) Sagittal T2 weighted images of the cervical cord showing T2 hyperintense lesion extending from the cervicomedullary junction to C6 vertebral level. (b) Axial T2 weighted images show that the hyperintensity occupies the entire cross-section of the spinal cord

DISCUSSION

Chikungunya fever is an arboviral illness caused by an RNA virus belonging to genus alphavirus and family togaviridae. The first outbreak of the Chikungunya fever occurred in Tanzania in 1952 and in India the first outbreak was reported in 1963 in Calcutta [1]. The recent epidemic started in March 2005 in French Island of Reunion and subsequently spread to India in December 2005 [1].

Chikungunya fever is mostly a benign self-limiting febrile illness. Though the neurological complications have been known since 1960s but they are rare and infrequent. Economopoulou et al., [2] reported neurological manifestations in 24.1% patients with Chikungunya infection whereas Chandak et al., observed it in 16.3% of patients [3] and Rampal et al., in as much as 33% patients [4]. The range of presentations includes encephalitis,

Guillain-Barré syndrome (GBS), cerebellar syndrome, myelitis, external ophthalmoplegia, facial palsy, sensorineural deafness, and optic neuritis. Encephalitis is the most common form of neurological involvement observed, occurring in more than 50% patients with neurological involvement with an overall incidence of 11% to 18% among patients with Chikungunya virus infection [3-5]. Myelitis was seen in only 7 out of the 300 patients with Chikungunya virus infection by Chandak et al., and in only 3 of the 60 patients with Chikungunya virus infection studied by Rampal et al., [3,4]. Wadia et al., described the following neurological manifestations reported in 359 patients seen at 5 centers: encephalitis (n = 175), neuropathy (n = 129), myelitis (n = 69), entrapment neuropathy (n = 34) and muscle injury described in 34 of 229 patients but it is not clear whether any of their patients had a combination of myelitis and myositis [6]. The combination of myelitis and myositis in Chikungunya infection has not been reported to the best of our knowledge.

Diagnosis of chikungunya in the present case was done on the basis of a positive IgM antibody for Chikungunya virus. The lack of confirmation of chikungunya by a real-Time Loop-Mediated Isothermal Amplification (RT-LAMP) – Polymerase Chain Reaction is a limitation of the report but because the patient presented to us 2 weeks after the onset of fever, a RT-PCR could have very well been negative. Moreover as per guidelines issued by National Institute of Communicable Disease, presence of virus-specific IgM antibodies in single serum sample in acute or convalescent stage can also be used as a confirmatory test for chikungunya in appropriate settings [7].

Animal experimental studies suggest that the fibroblast is the chief target cell of Chikungunya virus accounting for its tropism for muscles, joint and skin connective diseases [8]. Brett et al., demonstrated the role of macrophage derived products in the development of arthritis and myositis triggered by alpha virus

infection [9]. Though the pathophysiology of neurological involvement in Chikungunya infection has not been established but reports of association with neurological involvement and animal experimental studies strongly point towards neurotropism of the virus [7].

CONCLUSION

The case report emphasizes the fact that Chikungunya infection which is considered to be a benign illness should be considered as a possible etiology while evaluating patients with transverse myelitis more so in patients with a history of febrile illness with rheumatological manifestations. Also patients with chikungunya infection should be followed up for possible neurological complications.

REFERENCES

- [1] Chhabra M, Mittal V, Bhattacharya D, Rana U, Lal S. Chikungunya fever: a re-emerging viral infection. *Indian J Med Microbiol.* 2008;26(1):5-12.
- [2] Economopoulou A, Dominguez M, Helynck B, Sissoko D, Wichmann O, Quenel P, et al. Atypical Chikungunya virus infections: clinical manifestations, mortality and risk factors for severe disease during the 2005-2006 outbreak on Réunion. *Epidemiol Infect.* 2009;137(4):534-41.
- [3] Chandak NH, Kashyap RS, Kabra D, Karandikar P, Saha SS, Morey SH, et al. Neurological complications of Chikungunya virus infection. *Neurol India.* 2009;57:177-80.
- [4] Rampal, Sharda M, Meena H. Neurological complications in Chikungunya fever. *J Assoc Physicians India.* 2007;55:765-69.
- [5] Rajapakse S, Rodrigo C, Rajapakse A. Atypical manifestations of chikungunya infection. *Transactions of the Royal Society of Tropical Medicine and Hygiene.* 2010;104:89-96.
- [6] Wadia RS. A neurotropic virus (Chikungunya) and a neuropathic aminoacid (homocysteine) *Ann Indian Acad Neurol.* 2007;10:198-213.
- [7] National Institute of Communicable Disease, New Delhi. Chikungunya fever. CD Alert. 2006;10:6-8.
- [8] Murthy JMK. Chikungunya virus: The neurology. *Neurol India.* 2009;57:113-35.
- [9] Lidbury BA, Rulli NE, Suhrbier A, Smith PN, McColl SR, Cunningham AL, et al. Macrophage-Derived Proinflammatory Factors Contribute to the Development of Arthritis and Myositis after Infection with an Arthrogenic Alphavirus. *J Infect Dis.* 2008;197:1585-93.

PARTICULARS OF CONTRIBUTORS:

1. Professor, Department of Neurology, G.B. Pant Hospital, Delhi, India.
2. Senior Resident, Department of Neurology, G.B. Pant Hospital, Delhi, India.
3. Director, Professor, Department of Neurology, G.B. Pant Hospital, Delhi, India.
4. Director, Professor and Head, Department of Neurology, G.B. Pant Hospital, Delhi, India.
5. Senior Resident, Department of Neurology, G.B. Pant Hospital, Delhi, India.

NAME, ADDRESS, E-MAIL ID OF THE CORRESPONDING AUTHOR:

Dr. Neera Choudhary,
Department of Neurology, Academic Block, Room No. -503, G.B. Pant Hospital, New Delhi-110002, India.
E-mail : ashishduggal2005@rediffmail.com

FINANCIAL OR OTHER COMPETING INTERESTS: None.

Date of Submission: **Jan 19, 2015**

Date of Peer Review: **Apr 25, 2015**

Date of Acceptance: **Jun 26, 2015**

Date of Publishing: **May 01, 2016**